Adrenocortical carcinoma: a practical guide for clinicians

Martin Fassnacht, Soraya Puglisi, Otilia Kimpel, Massimo Terzolo

Lancet Diabetes Endocrinol 2025; 13: 438–52
Published Online March 11, 2025
https://doi.org/10.1016/S2213-8587(24)00378-4

Department of Medicine, Division of Endocrinology and Diabetes, University Hospital, University of Würzburg, Würzburg, Germany (Prof M Fassnacht MD, O Kimpel MD); **Comprehensive Cancer Center Mainfranken, University of Würzburg, Würzburg, Germany** (Prof M Fassnacht); **National Center for Tumor Diseases WERA, Würzburg, Germany** (Prof M Fassnacht); **Department of Clinical and Biological Sciences, Internal Medicine, San Luigi Hospital, University of Turin, Turin, Italy** (S Puglisi MD, Prof M Terzolo MD)

Correspondence to: Prof Martin Fassnacht, Department of Medicine, Division of Endocrinology and Diabetes, University Hospital, University of Würzburg, Würzburg 97080, Germany **fassnacht_m@ukw.de**

Adrenocortical carcinoma is a rare endocrine malignancy. The management of patients with adrenocortical carcinoma is challenging for several reasons, including its heterogeneous but frequently aggressive biological behaviour; tumour-related hormonal excess (eg, Cushing's syndrome or virilisation); the overall paucity of evidence regarding diagnostic investigation and treatment; the approval of only one drug (mitotane); and the scarcity of centres with sufficient experience. In this Review, we present 25 questions on the most important aspects of the clinical management of adult patients with adrenocortical carcinoma that we have frequently asked ourselves over the past 25 years. We offer our personal answers and perspectives, drawing upon published evidence as well as more than 60 years of collective clinical experience and insights from our management of more than 1700 patients across two centres in Germany and Italy.

Introduction

Adrenocortical carcinoma is a rare malignancy, in contrast to benign adrenal tumours, which are among the most common human neoplasias with a prevalence of greater than 3% in adults older than 50 years.[1] In this Review, we present and discuss the challenges involved in the management of patients with adrenocortical carcinoma, together with our personal recommendations regarding 25 of what we believe are the most crucial clinical questions. These questions arose during discussions of the key topics addressed in guidelines and frequently asked questions. The aim of this Review is not to provide a systematic review of the literature, but to present our personal views based on the publications available and our experiences of the management of adult patients with sporadic adrenocortical carcinoma. By doing so, we hope to provide guidance in navigating the uncertainty surrounding the scientific evidence. We have addressed the most important aspects of clinical practice. However, due to space restrictions, we are unable to cover many more basic or translational research topics.

The incidence of adrenocortical carcinoma is approximately 1–2 per million per year[2–4] and is more common in women (55–65%) than in men (35–45%).[2–6] Adrenocortical carcinoma poses unique challenges to physicians, who must tackle both tumour progression and hormone secretion, and it considerably affects life expectancy. The 5-year survival rate is generally poor, although it varies according to the European Network for the Study of Adrenal Tumours (ENSAT) stage (65–82% for stage I, 58–68% for stage II, 41–55% for stage III, and 10–20% for stage IV), with survival slightly improving in the past 20 years.[6–8] Due to the rarity of adrenocortical carcinoma, most of our knowledge comes from small, retrospective studies, which explains the limited progress in the comprehension of pathogenetic mechanisms, prognostication, and treatment.[9]

Clinical presentation and diagnostic investigation

(1) What are indicative clinical and biochemical findings for adrenocortical carcinoma?

Adrenocortical carcinoma is a multifaceted disease with different clinical presentations. Severe Cushing's syndrome combined with severe virilisation is at the extreme end of the spectrum, with randomly discovered asymptomatic tumours at the milder end. A clinically apparent overt endocrine syndrome can be found in up to 60% of patients,[10,11] however, frequency varies with referral and is higher in endocrine series than in oncological or surgical series because endocrine investigations are usually more comprehensive when done by endocrine departments.[6,10–13] Hormone-secreting adrenocortical carcinomas are more common in women or than in men, but androgen-producing adrenocortical carcinomas exist in men and can be overlooked because men have high endogenous testosterone and adrenocortical carcinoma-induced androgen secretion is usually negligible.[14]

Cortisol excess is the most common laboratory finding in adult patients with adrenocortical carcinoma and is frequently associated with autonomous secretion of androgens (or other steroids). A concomitant Cushing's phenotype and signs of sex hormone excess suggests adrenocortical carcinoma, as well as biochemical evidence of multiple steroid co-secretion. Another sign is a Cushing's phenotype with constitutional or cancer-related features. With a rapidly growing adrenocortical carcinoma or high tumour burden, cancer-related features can dominate over steroid-associated symptoms.

A nation-based survey in Italy published in 2023 revealed that presentation as adrenal incidentaloma is increasingly common and presented in 181 (38%) of the 475 patients.[6] In this group of patients, 46 (25%) showed biochemical evidence of autonomous cortisol secretion, despite not having classic Cushing's features.

(2) What are the strongly recommended diagnostic procedures in patients with suspected adrenocortical carcinoma?

In accordance with the European Society of Endocrinology–ENSAT and European Society for Medical Oncology (ESMO) guidelines,[15,16] we are convinced that a comprehensive diagnostic investigation is essential for best patient outcomes (panel 1). Although the cost-effectiveness of a detailed preoperative endocrine assessment has not been proven, we recommend it for four main reasons. First, the detection

of adrenal steroid excess might enable a non-invasive diagnosis of an adrenocortical tumour. Second, the steroid pattern might indicate that the adrenal lesion is probably malignant (eg, co-secretion of sex hormones and cortisol, secretion of steroid precursors, or elevated oestradiol in males are all highly suspicious for adrenocortical carcinoma).[17] Third, high concentrations of adrenal hormones before surgery could act as tumour markers during follow-up.[18,19] Finally, if autonomous cortisol secretion remains undiagnosed, complete resection might lead to life-threatening adrenal insufficiency. Using the recommended hormonal tests, only a minority of adrenocortical carcinomas are hormonally inactive. In non-secreting tumours, alternative diagnoses to adrenocortical carcinoma should be considered.

Adequate visualisation of the tumour and potential metastases is also crucial before any therapy. The guidelines on adrenal incidentalomas[1] state that a low tumour density (Hounsfield units ≤10) on unenhanced CT scans is still the best method for ruling out a malignant tumour. However, no imaging method can establish whether an adrenal mass is really adrenocortical carcinoma. In all patients with suspected adrenocortical carcinoma, abdominal, pelvic, and thoracic imaging is necessary, as overlooked metastases can lead to inappropriate treatment. In our centres in Germany and Italy, we frequently use [^{18}F]fluorodeoxyglucose PET and CT, including a full-dose diagnostic CT, and value the additional information provided by this method (unless there is massive metastatic spread). However, we are aware that such scanners are not widely available.

(3) When should adrenocortical carcinoma be suspected in patients with adrenal incidentaloma and what diagnostic steps should be taken?

Several clinical, biochemical, and radiological findings could suggest that an adrenal incidentaloma is an adrenocortical carcinoma. An adrenal tumour in a patient younger than 50 years (adrenal adenomas are mostly found in people >50 years), large tumour size (most adenomas are <4 cm), or the presence of constitutional or mass-related symptoms might indicate adrenocortical carcinoma.[20] However, all these criteria are non-specific. Therefore, all patients with suspicious clinical features or unilateral adrenal masses that cannot be diagnosed as benign based on established imaging criteria[1] should be investigated immediately using comprehensive endocrine and imaging investigations (panel 1).

Panel 1: Diagnostic investigations in patients with suspected or proven adrenocortical carcinoma (adapted from Fassnacht et al[16])

Hormonal investigations

- Glucocorticoid excess
  - 1 mg dexamethasone suppression test or free cortisol in 24 h urine*
  - Basal adrenocorticotropic hormone in plasma†
- Sex steroids and steroid precursors‡
  - Dehydroepiandrosterone sulphate
  - 17-hydroxyprogesterone
  - Androstenedione
  - Testosterone (only in women)
  - 17-β oestradiol (only in women who are postmenopausal and men)
  - 11-deoxycortisol
- Mineralocorticoid excess
  - Potassium
  - Aldosterone to renin ratio (only in patients with arterial hypertension or hypokalaemia, or both)
- Exclusion of a phaeochromocytoma
  - Fractionated metanephrines in 24 h urine or free plasma metanephrines

Imaging

- CT or MRI of abdomen and pelvis
- Chest CT
- [^{18}F]fluorodeoxyglucose PET or CT scans§
- Bone or brain imaging (when skeletal or cerebral metastases are suspected)

*1 mg dexamethasone test is the preferred method to exclude relevant hypercortisolism. However, if overt Cushing's syndrome is evident then cortisol measurements in 24 h urine could quantify cortisol excess. Alternatively, salivary or serum bedtime cortisol measurements can be used. †Adrenocorticotropic hormone measurements can be skipped if hypercortisolism is excluded. ‡The most suitable set of precursors and sex hormones has not yet been established, but we suggest broad liquid chromatography-mass spectrometry based steroid panels if available. §Not necessary in all patients, but helpful in patients with an undetermined adrenal mass or other potentially metastatic lesions.

Therapy: surgery

The primary aim of surgery for adrenocortical carcinoma is complete tumour removal (R0 resection) with negative margins. Achieving R0 resection is crucial for future outcomes and is usually the only chance of cure in patients with adrenocortical carcinoma.[15,16,21]

(4) What are the minimum surgical requirements for suspected adrenocortical carcinoma?

Although reliable studies on this topic are still few in number,[22,23] we are convinced that the surgeon's experience and the case volume of the entire perioperative team are paramount for a successful operation. The ESMO–European Network for Rare Adult Solid Cancers guidelines recommend that surgery for adrenocortical carcinoma should only be undertaken by surgeons who have done at least six adrenalectomies per year (preferentially >20) and have sufficient experience in oncological surgery.[15] We extended these non-specific recommendations in a 2022 review and recommend that patients with adrenocortical carcinoma should be referred to cancer centres with a minimal annual workload of 30 adrenalectomies, of which at least six are for adrenocortical carcinoma.[9]

(5) What is the best surgical approach?

Surgical techniques for adrenocortical carcinoma are debatable because of the location of the adrenal gland and its fragile capsule, making tumour rupture a major risk. As such, enucleation and partial adrenalectomy is contraindicated in the management of any suspected or proven adrenocortical carcinoma.[21] The extent of the surgical approach largely depends on the tumour burden and disease stage. For resectable cases, extensive en bloc resection is recommended, but the kidneys should not be removed when there is no invasion.[24]

Open adrenalectomy is the standard approach in adrenocortical carcinoma to ensure complete tumour removal.[15,16,21,25–27] Although minimally invasive methods are standard for benign tumours,[1] there is debate regarding laparoscopic adrenalectomy for adrenocortical carcinoma. In some studies, minimally invasive surgery has been associated with a higher frequency of R1 surgery and peritoneal carcinomatosis.[25,28,29] However, meta-analyses in the past 9 years have reported no significant adverse outcomes in tumours resected by minimally invasive surgery.[25,30–32] In our experience, rather than choosing between open or minimally invasive surgery, it is more important that the surgeon has considerable experience in adrenal surgery and adheres to the principles of oncological surgery.

There is no general consensus regarding the optimal extent of regional lymph node resection during primary resection.[21,33,34] Its effect on survival varies across retrospective cohort studies, but overall these studies suggest an improved outcome with lymphadenectomy.[35] We thus recommend that lymphadenectomy should be done, including at least the periadrenal and hilar nodes in all patients with suspected adrenocortical carcinoma, although the best extent of lymphadenectomy is still uncertain.[36–38]

(6) Which patients are eligible for neoadjuvant treatment?

In other types of cancer, initially unresectable tumours might become resectable after neoadjuvant therapy. However, all retrospective studies in adrenocortical carcinoma have selection bias and cannot answer this question, although they point towards some benefit.[8,39] Arguments in favour of neoadjuvant therapy include initiating systemic therapy at the earliest possible time, decreasing tumour size to increase the probability of R0 resection and minimise the magnitude of operation required, and biological selection of patients to operate only on those who have responded to induction therapy.[8,39,40]

Deciding which patients should be offered a neoadjuvant approach is highly challenging and requires a careful multidisciplinary discussion. The risks of extensive surgery should be weighed against the low chance of a response to chemotherapy. Immunodepression following extensive surgery could favour metastatic spread and, in our experience, surgery in patients whose disease has been at least stabilised by chemotherapy leads to a better outcome. Therefore, in most patients in whom complete resection of all tumour lesions is uncertain, we recommend first administering systemic therapy (usually with etoposide, doxorubicin, cisplatin, and mitotane (EDP-M); question 18) and then re-evaluating resectability after 2–6 cycles of chemotherapy. However, severe Cushing's syndrome might be a factor against chemotherapy due to the high risk of sepsis. Consequently, surgery that can rapidly abate cortisol secretion could be preferable. In these patients, we are increasingly using a short course of rapidly acting, potent inhibitors of steroidogenesis (ie, metyrapone or osilodrostat) given in high doses to control cortisol excess before administering a definitive treatment of either surgery or chemotherapy. The main argument against neoadjuvant therapy is that a completely resectable tumour could become unresectable in the case of progression, despite treatment.

(7) What is the case for using debulking surgery in patients with metastatic adrenocortical carcinoma?

Cohort studies on debulking surgery tend to have bias. Interdisciplinary teams recommend surgery to one patient, but not to another depending on the experience of the physicians, which cannot be controlled for in retrospective studies. We are therefore not convinced of the benefit of debulking surgery, although a few studies suggest a positive effect.[41,42] In our centres, we offer surgery to patients with metastatic disease only if they have severe hormone excess that cannot be otherwise controlled, and if about 80% of the tumour burden can be removed safely.[16] Other exceptions are patients with a perceived risk of local complications without other treatment options, such as radiotherapy. However, if systemic therapy is successful, the possibility of surgery should be re-assessed during follow-up.

Histopathology and prognosis

(8) What information from pathology reports is important?

Securing a pathological diagnosis of adrenocortical carcinoma is not easy; the rate of misdiagnosis was found to be between 9% and 13% in two series from Italy and Germany that underwent expert pathological review.[43,44] It is often difficult to differentiate between adrenocortical carcinoma and non-cortical tumours. Immunohistochemistry for steroidogenic factor-1, the most specific marker of adrenocortical tumour origin, is the most helpful approach in making this differentiation.[45] Pathological assessment should include the Weiss score,[46,47] which considers nine specific histological features of the tumour on haematoxylin and eosin-stained slides (high nuclear grade, >5 mitoses per 50 high power field, atypical mitoses, clear cells being <25% of the total cells, diffuse architecture in more than

33% of the tumour, necrosis, venous invasion, sinusoidal invasion, and capsular invasion). If this score is 3 or more points, the diagnosis of adrenocortical carcinoma can be assumed to be confirmed.

Although the Weiss score is the most widely used system, it is not standardised and the assessment of some characteristics is subjective.[48] Other diagnostic systems have been proposed to overcome this limitation, such as the van Slooten index,[49] the modified Weiss score,[50] the Helsinki classification,[51,52] and reticulin staining.[53] It is unknown which system is the most accurate and experienced pathologists often use a combination. For oncocytic tumours that, according to the Weiss score would always be classified as malignant, the Lin–Weiss–Bisceglia system[54,55] should be used for accurate assessment.

Standard pathological assessment also includes immunohistochemistry for the proliferation factor Ki67 in tumour areas of higher proliferation, since Ki67 counting is key for establishing prognosis.[56] Ki67 immunohistochemistry has become more popular than a mitotic count for prognostication, although there is interindividual variability in the scoring. Digital image analysis systems have thus been proposed for a more reproducible and reliable assessment,[57,58] but are not widely available.

(9) Which prognostic factors help in selecting the appropriate treatment?

Prognostication in adrenocortical carcinoma is primarily based on tumour stage, resection status, and Ki67 labelling (figure 1 and appendix p 7).[16] The ENSAT staging system[7] is easy to use and, given its superior prognostic capability compared with the TNM system,[59] has been endorsed by guidelines.[15,16] The presence of metastatic disease (stage IV) is the worst prognostic factor and usually makes radical surgery impossible. In patients with stage IV adrenocortical carcinoma, prognosis can be stratified by the number of metastatic organs and by using a comprehensive Grade, Resection status, Age, and Symptoms (GRAS) score.[60] A modified version of this score also includes stage (S-GRAS). The application of S-GRAS in a large retrospective series of 942 patients with adrenocortical carcinoma who underwent surgery led to a more granular and accurate prediction of survival compared with the use of Ki67 index or tumour stage.[61]

With localised (stage I–III) adrenocortical carcinoma that has been radically resected (R0 microscopically margin-free resection), the Ki67 index is the most important determinant of prognosis (figure 1C).[56] A prognostication scheme based on localised stage, R0 resection, and low grade (Ki67 ≤10%) adrenocortical carcinoma was prospectively applied by the ADIUVO trial, which validated the cutoff for Ki67 of less than or equal to 10% as a criterion for a good prognosis.[62] It is not clear if excess cortisol is linked to worse outcomes.[6,10,12,63–65]

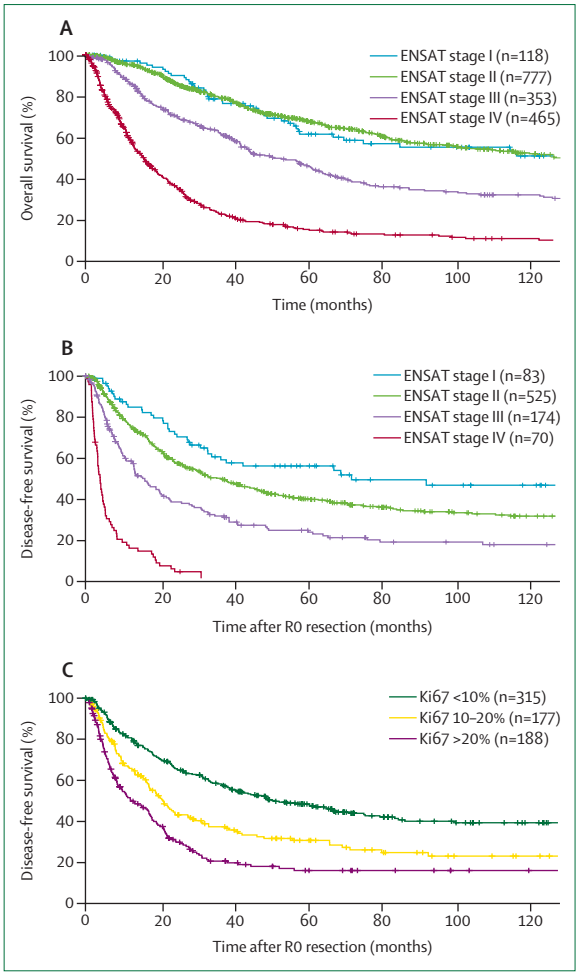

Figure 1: **Survival of patients with adrenocortical carcinoma**
(A) Overall survival according to ENSAT tumour stage (N=1713). (B) Disease-free survival after R0 resection (N=852). (C) Disease-free survival after R0 resection according to Ki67 proliferation index (N=680). Data derived from patients treated in our two centres from 2000–24. For Cox regression analyses see appendix p 7. ENSAT=European Network for the Study of Adrenal Tumours.

See Online for appendix

This uncertainty is possibly due to the different methods used to categorise hormone secretion.

Within the general framework of a poor prognosis, there is increasing awareness that the course of adrenocortical carcinoma is heterogeneous. The classic prognostic factors do not fully explain this variability; studies have stratified patients with adrenocortical carcinoma into separate clusters with different prognoses based on the molecular signatures of adrenocortical carcinoma using high-throughput omic technologies.[66–69] Evidence from the past 15 years suggests that the assessment of germline variants might reveal an unsuspected familial pattern of adrenocortical carcinoma and could add prognostic information.[70,71] Understanding the specific molecular and genetic characteristics of adrenocortical carcinoma is an important research avenue that must be transferred to clinical practice.

Postoperative management

(10) How should patients be followed up after complete surgical resection?

Given the scarcity of studies comparing different surveillance protocols, most expert centres use cross-sectional imaging of the thorax, abdomen, and pelvis, and hormonal investigations every 3 months for 2 years.[16] We use [^{18}F]fluorodeoxyglucose PET and CT when the results of cross-sectional imaging are not conclusive regarding disease recurrence and when surgery is used to treat recurrent adrenocortical carcinoma to establish disease extent. We then increase the follow-up interval stepwise and, 5 years after surgery, we monitor patients annually up to year 10, when we usually stop surveillance in patients without recurrence.

(11) Which patients are candidates for adjuvant mitotane?

Adrenocortical carcinoma has a propensity to recur, even after radical surgery, which supports adjuvant approaches.[72] We thus recommend postoperative, adjuvant mitotane treatment in all patients, except when the perceived risk of recurrence is low (figure 2). This recommendation follows the conclusions of guidelines to date[15,16] and is current practice at most expert centres.[73] However, given that studies have been retrospective in design and heterogeneous in patient characteristics, there is insufficient evidence for a strong recommendation (appendix p 2). Despite some heterogeneous findings, the use of adjuvant mitotane is supported by two meta-analyses.[16,83] Another retrospective study showed that the use of adjuvant mitotane was associated with prolonged

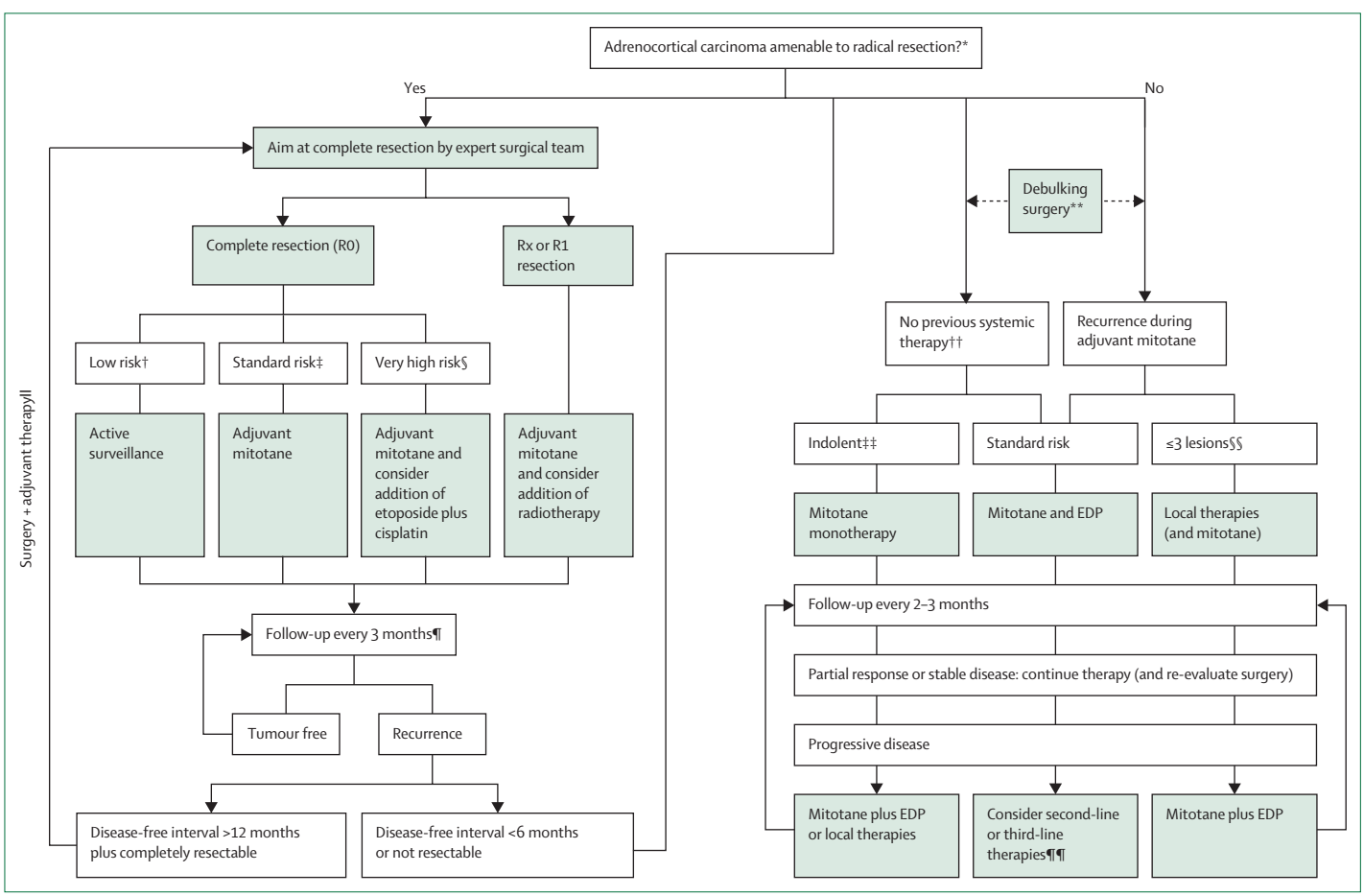

Figure 2: **Treatment flow chart for adrenocortical carcinoma**

If clinical trials are available, inclusion in these trials should always be considered. EDP=etoposide plus doxorubicin plus cisplatin. ENSAT=European Network for the Study of Adrenal Tumors. *All patients with stage I and II and most patients with stage III adrenocortical carcinoma should be considered for radical resection. If complete resection is not feasible, consider neoadjuvant treatment (eg, mitotane plus cisplatin or EDP). In selected patients with single metastases, complete resection might also be possible. In patients with R2 resection, consider re-surgery by an experienced surgeon. †ENSAT stage I or II and Ki67 ≤10%. ‡ENSAT stage I or II and Ki67 between 11% and 30%, or ENSAT stage III and Ki67 <30%. §Any of the following: Ki67 ≥30%, large tumour thrombus in the vena cava, stage IV, or R1 resection. ¶See main text question 10. ||After recurrence, we recommend adjuvant therapy in all patients (depending on previous treatment of mitotane, mitotane plus etoposide plus cisplatin, or mitotane plus radiotherapy in cases of local recurrence). **Only in selected patients (eg, with severe hormone excess). ††Or >12 months after previous systemic therapy. ‡‡Low tumour burden (<10 tumoural lesions and <3 affected organs) and a disease-free interval >1 year after initial radical therapy. If only 1–3 lesions <5 cm are present, addition of local therapy might be appropriate. §§Most local therapies are more effective if the lesions are <5 cm maximal diameter. In specific patients, local therapy might also be useful, if more than three tumoural lesions are present. Mitotane should be continued if clinical benefits can be assumed (or if the mitotane plasma concentration never reached >10 mg/L) and tolerability is acceptable. ¶¶See panel 2.

recurrence-free survival in a monocentric series of 152 patients. The benefit on survival was particularly evident for patients with stage III adrenocortical carcinoma and a Ki67 proliferation index greater than 10%.[84] Mitotane is given at incremental doses during the initial weeks of treatment. In our centres, we use slightly different regimens: the low dose in Orbassano, Italy, and the high dose in Würzburg, Germany (panel 3). Dose adjustments are mainly driven by patient compliance and monitoring of plasma mitotane concentrations aimed at targeting concentrations higher than 14 mg/L. We recommend giving mitotane for at least 2 years, which is when most recurrences occur. Thereafter, mitotane can be continued for up to 5 years in patients at high risk of recurrence who have good compliance and tolerability. Data from a retrospective study support this recommendation.[85]

(12) For which patients can adjuvant therapy be omitted?

In the ADIUVO trial, patients who underwent a R0 resection of localised (stage I–III), low-grade (Ki67 ≤10%) adrenocortical carcinoma were randomly allocated to active surveillance or adjuvant mitotane, but showed no significant treatment benefit. However, the trial showed that patients with these features had a better prognosis than expected, with 5-year recurrence-free survival around 75% in both groups.[62] Given the outcome of the ADIUVO trial and our experience, we proposed a new stratification prognosis scheme to guide post-operative management (figure 2). In our scheme, only stage I–II adrenocortical carcinomas (R0 and Ki67 ≤10%) are considered low risk. This category accounts for approximately 30% of patients who are operated on and can be managed with active surveillance. Because only a few patients with stage III adrenocortical carcinomas were included in the ADIUVO trial and there is evidence that stage III is a poor prognostic factor,[7] adjuvant mitotane treatment might still be considered on an individual basis, particularly if the patients are younger than 50 years and fit.[9]

(13) Which patients might benefit from adjuvant cytotoxic chemotherapy?

Data are scarce on adjuvant therapy with cytotoxic drugs in patients with adrenocortical carcinoma,[86–88] and the first two studies on this topic included only four patients and 11 patients. In a study published in 2021, 31 patients with a very high risk of recurrence (eg, median Ki67 30%) who were treated with a platinum-based therapy were retrospectively included.[88] Two different statistical approaches (comparison with 31 matched control individuals and propensity matching with 268 control individuals) suggested a much better recurrence-free survival and overall survival in the patients who received chemotherapy than patients who were treated according to current standards (90% received adjuvant mitotane; appendix p 2). A prospective single-arm study in children and adolescents also showed beneficial effects of adjuvant platinum-based chemotherapy in patients with stage III adrenocortical carcinoma.[89] However, these scarce data do not prove that adjuvant cytotoxic therapy is beneficial in adrenocortical carcinoma. We therefore encourage all clinicians to enrol all suitable patients in the randomised ADIUVO2 trial (NCT03583710; open at the time of writing this Review), or transfer them to participating centres. Major inclusion criteria are stage I–III adrenocortical carcinoma after radical resection (R0, Rx, or R1 resection) with Ki67 greater than 10%. However, when enrolment is not possible, we recommend four cycles of cisplatin and etoposide in addition to mitotane in patients at very high risk of recurrence (figure 2).

(14) Is it worth using adjuvant radiotherapy?

Because local recurrences are common in patients with adrenocortical carcinoma, even after complete resection, adjuvant radiotherapy appears to be a feasible treatment approach. Most studies on this topic show that adjuvant radiotherapy reduces the risk of local recurrence. However, only some of the studies showed an improvement in both recurrence-free survival and overall survival,[90–93] which was not supported by other studies[94–96] (appendix p 2). We are currently thus using adjuvant radiotherapy primarily in patients without distant metastases if there is a microscopically or macroscopically incomplete resection, or after local recurrence surgery. In both resection groups, the risk of repeat local recurrence appears to be high and surgery is even more difficult after a rupture of the tumour capsule. If the spread of the

Panel 2: **Recommended systemic therapies for adrenocortical carcinoma***

Adjuvant treatment options (for indication see questions 11–13)

- Oral mitotane monotherapy[73]
- Adjuvant treatment with cisplatin, etoposide, and mitotane (ADIUVO-2 study)

First-line therapies for advanced adrenocortical carcinoma (for indication see questions 18–19)

- First-line therapies
  - Mitotane monotherapy[11,74]
  - Etoposide, doxorubicin, and cisplatin plus mitotane[75]
- Second-line and third-line therapies
  - Streptozocin plus mitotane[75]
  - Gemcitabine plus capecitabine[76,77]
  - Pembrolizumab[78,79]
  - Cabozantinib[80,81]
  - Temozolomide[82]

*For more details see appendix p 5. For more information on the management of mitotane see panel 1.

Panel 3: Management of mitotane therapy

Dosage and monitoring

- The exact starting dose schedule depends on the patient's and physician's preferences.*
- Starting with high-dose regimen: 1·5 g on day 1; 3·0 g on day 2; 4·5 g on day 3; and 6·0 g on day 4.
- Starting with low-dose regimen: 1·0 g on day 1 and increase by 0·5 g every 3–4 days up to a total dose of 3·0–4·0 g/day.
- Afterwards, the dose will be adjusted to tolerability, aiming for mitotane blood concentrations >14 mg/L.
- Consider reducing the previously tolerated dose if adverse effects occur that are not responsive to mitigating treatment. The mitotane dose can be up-titrated when symptoms improve.
- Consider temporary discontinuation in the event of grade 3–4 toxicity. Mitotane can be cautiously reintroduced after a therapeutic holiday.
- Assessment every 3–4 weeks, with a physical examination and laboratory tests (blood count and assessment of electrolytes, liver enzymes, renal function, hormones, and lipids)†; after 3–6 months these intervals can be extended.
- Mitotane blood concentration should be monitored every 6–9 weeks (more frequently in the first few months or in the case of toxicity).
- Key adverse effects are adrenal insufficiency, asthenia or fatigue, nausea or vomiting, diarrhoea, anorexia, dizziness or vertigo, cognitive impairment, increase in liver function tests, induction of cytochrome P450 enzymes (can cause substantial drug-to-drug interactions), elevation of cortisol binding globulin and sex hormone binding globulin (might confound hormone assessment), elevation of cholesterol and triglycerides, ovarian cysts, potential teratogenic effect in premenopausal women, gynaecomastia, and reduction in libido in men.

Supportive therapy

- High-dose glucocorticoid replacement in all patients (on long-term treatment, most patients require 50–60 mg hydrocortisone per day, but some require up to 100 mg/day).
- Mineralocorticoid replacement is needed in approximately 30% of patients receiving chronic therapy.
- Metoclopramide and loperamide in most patients and eventually ondansetron and proton pump inhibitors.
- Provide effective barrier contraception methods in women of childbearing age.
- Other supportive therapies (eg, testosterone, thyroxine, and statins) remain controversial.

Management of unwanted effects‡

- Prompt palliation of gastrointestinal symptoms with specific treatment.
- Consider increase in glucocorticoid dose in cases of nausea, asthenia, or fatigue and very high adrenocorticotropic hormone concentrations (>250 pg/mL).
- Consider mineralocorticoid replacement in patients with very high renin concentrations or high potassium, gait instability, dizziness, and orthostatic hypotension, or a combination thereof.
- Consider testosterone replacement in symptomatic men with low testosterone concentrations.
- Consider statin therapy in patients at low risk of recurrence on adjuvant treatment.
- Consider thyroxine replacement in the case of relevant reduction below the normal range in free thyroxine concentrations.
- Consider folate and vitamin B12 supplementation in patients with anaemia and deficiency.

*We do not know which regimen is optimal. Differences between the two schemes pertain to the first months of treatment. Thereafter, many patients have stable blood mitotane concentrations with 1–4 g/day and show have good tolerability to treatment. †Hormones include adrenocorticotropic hormone, renin, thyroid-stimulating hormone, free thyroxine, and testosterone. ‡Approximately 20% of patients prematurely discontinue treatment in the adjuvant setting due to toxicity.[62]

tumour is restricted and localised, radiotherapy might be the appropriate approach. Otherwise, adjuvant treatment with mitotane plus four cycles of cisplatin and etoposide is appropriate. Another question is whether mitotane, platin-based chemotherapy, and radiotherapy should be combined in the adjuvant setting for patients at high risk of recurrence. We are cautious in this regard and only rarely follow this triple therapy approach at our centres in young and fit patients.

(15) What is the right treatment for patients after incomplete surgery?

This scenario can present in a spectrum of conditions. If metastatic lesions remain after surgery, they should be treated following the recommendations for advanced adrenocortical carcinoma (see questions 17–21). If macroscopic remnants from the primary tumour are present, radiotherapy combined with mitotane (with or without platin-based chemotherapy) is usually the best option. Sometimes, a reoperation might be necessary, particularly if lymphadenopathy is present. However, we do not recommend a second surgery after R1 resection, but prefer adjuvant radiotherapy.

(16) How should patients with recurrent adrenocortical carcinoma be managed?

Postoperative disease recurrence is frequent, even when patients with adrenocortical carcinoma are managed in high-volume centres with expert surgeons and evidence-based adoption of adjuvant measures.[97,98] In retrospective studies, locoregional treatment of recurrence has been associated with better outcomes compared with systemic

treatment.[99,100] However, such findings might be subject to selection bias. Less aggressive adrenocortical carcinoma might be over-represented in cohorts of patients treated with locoregional therapies, meaning that tumour biology could contribute to these findings. The duration of disease-free survival after primary surgery is associated with the pattern of disease recurrence, because adrenocortical carcinoma recurs more frequently at multiple sites within 12 months after surgery.[99,100] We recommend surgical extirpation of recurrent adrenocortical carcinoma whenever feasible with radical intent (ie, when only one or a few tumoural lesions are present) and when recurrence does not occur too early in the postoperative period.[16] The time limits informing the choice between systemic and locoregional treatments are arbitrary. Current guidelines[15,16] recommend systemic treatment with no surgery if the disease-free interval is shorter than 6 months, and surgery or other locoregional treatments if the disease-free interval is longer than 12 months. If the interval is between 6 months and 12 months, the decision is individualised. Surgery can be used in combination with other interventional techniques and mitotane is usually introduced thereafter.

Management of advanced adrenocortical carcinoma

In this Review, we use the term advanced adrenocortical carcinoma for scenarios in which not all tumour lesions can be surgically removed. This scenario is true for most, but not all patients with stage IV adrenocortical carcinoma, but also for some patients with stage III tumours and many patients with recurrent disease. Details regarding the recommended systemic therapies are given in panel 2 and the appendix (p 4).

(17) What is the role of local therapies in patients with metastatic adrenocortical carcinoma?

Despite little evidence, we are convinced of the beneficial effects of local therapies—such as radiotherapy and different types of ablation or embolisation—in specific patients with advanced adrenocortical carcinoma. These therapies can be effective as palliative treatments for pain, neurological symptoms, or the prevention of short-term complications. However, there is an increasing body of evidence (exclusively from retrospective studies) that recommend disease control (including partial or even complete responses) by radiotherapy, radio-frequency, microwave transarterial embolisation or chemoembolisation, cryoablation transarterial embolisation or chemoembolisation, or radioembolisation.[101]

Toxicities have been reported within the expected ranges in most studies on other cancer types. Most were graded as 1–3 with few grade 4 events,[101] but the retrospective nature of the studies might have led to under-reporting. Only a few studies investigated predictive factors for treatment response. Smaller lesions (<3 cm or <5 cm) and a longer disease-free interval after primary surgery seemed to be the most important predictive factors.[101] For radiotherapy, we recommend either stereotactic treatment with at least 35 Gy, or conventional therapy with 50–60 Gy.[102,103] Overall, these studies and our experiences indicate that most local therapies are effective in adrenocortical carcinoma. Local therapies should therefore be considered more frequently, either alone or in combination with other therapies in advanced adrenocortical carcinoma. The best treatment depends on the individual patient and the medical expertise available. Prospective studies are needed to provide more evidence for these underused treatment options for patients with metastatic adrenocortical carcinoma.

(18) What is the best first-line systemic treatment for patients with advanced adrenocortical carcinoma?

Mitotane is an important therapeutic option for inoperable or metastatic adrenocortical carcinoma and is usually recommended as a monotherapy in cases of low tumour burden or less aggressive disease.[11,15,16,74] A multicentre cohort study investigated the efficacy of mitotane monotherapy in 127 patients with advanced adrenocortical carcinoma and showed an overall response rate of 20·5%, a median progression-free survival of 4·1 months, and overall survival of 18·5 months.[11] Using a multivariate analysis, a low tumour burden (<10 lesions) and a disease-free interval greater than 1 year after initial radical therapy were identified as the best predictive markers.[11]

However, the therapy with the strongest published evidence is EDP-M, which is therefore considered the first-line therapy in most patients with advanced adrenocortical carcinoma.[15,16] In the first ever randomised trial in adrenocortical carcinoma with more than 300 patients, this combination indicated a significantly longer progression-free survival compared with streptozocin plus mitotane (5·0 *vs* 2·1 months). In addition, an objective tumour response occurred in 23·2% of patients in the EDP–M group compared with 9·2% in the streptozocin group.[75] Patients who received both therapies had almost identical overall survival rates, irrespective of which regimen was given in the first line (hazard ratio 1·06; 95% CI 0·76–1·47). However, among patients who received only one treatment, overall survival in the EDP-M group was significantly better than in the streptozocin group (17·1 *vs* 4·7 months; p=0·004). These results highlight that in patients with less advanced or less aggressive disease (eg, expected survival >6 months), EDP-M might be used as a second-line treatment, which could allow experimental drugs to be first-line treatments.

(19) What should be done for patients that do not respond to first-line therapy?

More than 50% of patients with advanced adrenocortical carcinoma have progressive disease within 6 months

after starting first-line therapy, making this an important and frequent question for patients and physicians. However, the evidence behind our recommendations is weak and therefore reflects our personal experiences. Our first choice is always to enrol patients in a clinical trial, despite the scarcity of specific trials, as this approach was found to benefit patients in a French series published in 2023.[104] When availability and costs are not an issue and molecular data from the individual tumour does not provide strong evidence, we offer our patients five treatment options (checkpoint inhibitors, gemcitabine plus capecitabine, streptozotocin, cabozantinib, or temozolomide).[75–82,105–108] None of these options are particularly effective (appendix p 5), but we have seen individual patients benefit (eg, disease control for more than 12 months), some even after not responding to several previous regimens.

From the patient's perspective, immunotherapy and tyrosine kinase inhibitors seem to be good options. Responses in prospective trials with immune checkpoint inhibitors have been heterogeneous, however, a small subset of patients responded very well and the toxicity is, on average, lower than that of mitotane or cytotoxic drugs.[78,79,105–109] Tyrosine kinase inhibitors are rapidly metabolised if mitotane is still detectable in the blood due to the well established strong induction of CYP3A4 by mitotane,[110] which is most likely why most trials with tyrosine kinase inhibitors have failed to date.

However, a retrospective series[80] and a phase 2 trial[81] highlighted the efficacy of cabozantinib. In the 18 patients in the prospective trial, the median progression-free survival was 6 months and the overall survival was 24 months (including two patients with partial responses). We therefore increasingly tend to stop mitotane treatment after a second clinically significant progression (especially if mitotane blood concentrations are >14 mg/L). One disadvantage of both tyrosine kinase and checkpoint inhibitors is the high cost compared with the less expensive temozolomide and gemcitabine plus capecitabine. Temozolomide has good tolerability, is taken orally, and is therefore the most frequently used second-line therapy at our centre in Orbassano to date.

In patients progressing after all these therapies, salvage therapy is individualised and, in some patients, best supportive care is the most satisfactory approach. However, we have treated many young patients in good clinical conditions who request active treatment. In some cases, the treatment options that we discuss as future options could be individually considered.

(20) Can we predict the response to therapy?

If we were able to identify in advance which patients would benefit from a given therapy, we could tailor treatment. However, apart from mitotane blood concentrations (question 22), there is no predictive marker for routine clinical use. Several groups have investigated markers in tissues or blood to establish whether patients are more prone to respond to specific drugs. Initial results for some biomarkers are promising, but none have yet been substantiated in validation studies.[111]

(21) Should tumour sequencing be used to support therapeutic decisions?

Molecular profiling as a tool to identify potential treatment targets is an emerging field in oncology. This approach is most successful when the tumours have specific molecular vulnerabilities that can be attacked by targeted agents (eg, activating mutations of tyrosine kinase receptors). In the past decade, sequencing and other omic studies have greatly improved our understanding of the pathophysiology of adrenocortical carcinoma.[69,112–114] There is increasing evidence that there are probably three molecular subtypes bearing differential regulation of the cell cycle, Wnt–β-catenin signalling, and epigenetics, as well as different activities of the intratumoural steroid machinery and heterogeneous infiltration of immune cells.[115–117]

But why can this major increase in knowledge not yet be transferred to clinics to improve patient care? Our centre in Würzburg has conducted genome-wide analyses of more than 100 adrenocortical carcinoma samples. Unfortunately, molecularly informed treatments that lead to clinical benefits could be only initiated in a small subset of patients. Although a detailed analysis is still pending, the primary reasons why suitable therapies could not be initiated include insufficient druggable targets; potentially promising drugs could not be applied due to the predicted interaction with mitotane; the clinical condition of the patient had deteriorated substantially; and health insurance companies refused to cover drugs that had never been clinically investigated in adrenocortical carcinoma. The latter restriction applies to many countries, including Italy, where a restrictive policy on the off-label use of newly developed, expensive cancer drugs restricts the applicability of tumour sequencing.

Molecular profiling cannot therefore be recommended yet as standard of care in adrenocortical carcinoma. However, we often offer this option because there are individual patients who benefit from molecularly derived therapies (eg, enabling them to be included in clinical trials),[118] which might pave the way for future clinical studies.

Management of mitotane therapy

(22) How should patients receiving mitotane treatment be monitored? How could tolerability to mitotane be improved?

A major issue with mitotane therapy is the associated toxicity. In our practice, we carefully explain to our patients the potential toxicity of mitotane and how to address it before attaining their informed consent to treatment. Despite this toxicity, fewer than 15% of patients refuse treatment due to potential adverse events.

In the ADIUVO trial on patients at low risk of recurrence, fewer than 30% of potentially eligible patients refused randomisation because they feared treatment-associated toxicity. All patients randomised to adjuvant mitotane had several adverse events, although no severe toxicities were observed. The ADIUVO trial showed that management of adjuvant mitotane treatment is challenging even in expert centres, since 19% of patients had to discontinue treatment, and supported the pattern of adverse events observed in previous retrospective studies[62] (panel 3). Following the idea that high volumes of patients lead to better management (question 4), we advise patients on mitotane to be supervised in centres with a minimum of ten (preferably 20) patients managed with mitotane annually. To limit toxicity, patients should be offered comprehensive supportive therapy and appropriate education to recognise and treat adverse effects rapidly.

Due to the adrenostatic property of mitotane and the strong CYP3A4 induction, a high-dose glucocorticoid replacement (eg, 50–60 mg hydrocortisone per day) is usually required to prevent adrenal insufficiency. Additional mineralocorticoid replacement is only necessary in a subset of patients who can be identified by increased renin and borderline or high potassium.

Mitotane frequently alters many laboratory parameters, including thyroid tests, gonadal tests, and lipid profiles.[119–121] Testosterone or thyroxine supplementation and statin therapy are therefore used at some centres, but not all, because the clinical benefits are not well documented. However, additional supportive therapy to alleviate gastrointestinal symptoms is often needed[14] (panel 3). Management of mitotane treatment includes monitoring the plasma concentrations of the drug based on the therapeutic window theory. This theory originated more than 30 years ago from studies that showed that plasma mitotane concentrations above 14 mg/L were associated with treatment efficacy, while concentrations higher than 20 mg/L were associated with severe neuropsychological toxicity. These thresholds were arbitrarily defined in small studies prone to selection bias and other methodological problems.[122] However, there is evidence that both objective responses and neurological impairment due to mitotane occur at lower concentrations.[11,123] Therefore, the widely accepted 14–20 mg/L therapeutic range has come under scrutiny.[122] Because a substantial number of patients do not manage to reach such concentrations (approximately 40% in the ADIUVO study[62]), individualised treatments should be the main focus, not target concentrations. Periodic monitoring will assist in customising the dose for each patient, although the precise thresholds for effectiveness remain unclear.

Supportive care

(23) Which therapeutic measures are needed in addition to anticancer treatments?

In addition to psycho-oncological support (question 24), it is important to appropriately manage the adverse effects of mitotane (question 22) and other treatments. These measures include antiemetics and, in specific patients, granulocyte colony-stimulating factor during cytotoxic therapy.[124,125] More specific to adrenocortical carcinoma is the active treatment of the relevant hormone excess. Severe hypercortisolism is of particular concern, as its clinical sequelae (eg, hypokalaemia, risk of infection, and mood disorders) affect patient survival and quality of life. Although mitotane has an inhibitory effect on steroid synthesis, it can take weeks or months to achieve adequate control of hypercortisolism. Therefore, other steroidogenesis inhibitors with a more rapid onset of action might be needed, including metyrapone, osilodrostat, or ketoconazole.[126–128] For patients with bone metastases, at our centres we use bisphosphonates or denosumab on an individual basis to prevent complications. There is, however, no definitive proof of their effectiveness in reducing skeletal-related adverse events or improving overall survival in patients with adrenocortical carcinoma.[129] Finally, appropriate pain management is required.[130]

(24) When do patients require psycho-oncological support?

An assessment of psychosocial distress and individual psycho-oncological support and treatment needs should take place as early as possible and throughout the course of the disease. Health-related quality of life is an emerging topic in oncology. However, specific studies on adrenocortical carcinoma are scarce. The ADIUVO trial showed that adjuvant mitotane treatment negatively affects the quality of life of treated patients.[62] A Dutch study has drafted an adrenocortical carcinoma-specific health-related quality-of-life questionnaire[131] and more studies on patient-reported outcomes are needed. Until then, we follow the general recommendations of cancer societies[132] and offer our patients psycho-oncological support at an early stage. In many comprehensive cancer centres, different professional groups collaborate with each other, including psychologists, social workers, physical therapists, specialised nurses, and physicians with different specialties. Psychologists close to the patient's home also must be involved.

(25) Which patients should be offered best-supportive care and which should be offered palliative care?

Palliative care should be considered early in the disease course of patients with cancer alongside curative treatments, thus not only in the end-of-life period. In a patient-centred care programme, palliative care should be implemented as the preventive management of psychological distress and physical symptoms, with the aim of improving the quality of life of patients and their families.[133,134] We have included a palliative medicine specialist in our multidisciplinary teams. However, the early integration of palliative care in the treatment of patients with adrenocortical carcinoma is

Search strategy and selection criteria

References for this review were identified through a search of PubMed for articles published from Jan 1, 1950, to Aug 15, 2024, using the search terms "adrenocortical carcinoma" and "adrenal cancer". We also searched the Cochrane and Medscape databases with the same search parameters. We included mainly articles published in English from Jan 1, 2004, to Aug 15, 2024, but still included relevant and highly referenced older publications.

underdeveloped. To date, we consider palliative care for patients with advanced adrenocortical carcinoma and poor performance status (ECOG 3 or higher), in patients reporting intense symptomatology after chemotherapy or due to cancer progression (eg, vena cava syndrome), and in cases of severe distress associated with a diagnosis of adrenocortical carcinoma.[135] An important step in palliative medicine is the discontinuation of treatments associated with unbearable adverse events, and we are now discontinuing mitotane earlier than in previous years. An issue specific to patients with adrenocortical carcinoma is the treatment of Cushing's syndrome, which can be associated with severe symptoms and distress for affected patients. We therefore try to control symptoms that greatly affect wellbeing and for patients whose anticancer treatments have been stopped to improve their quality of life.

Conclusions and future perspectives

The evidence behind many of our recommendations in this Review has not yet been sufficiently supported and more prospective studies (both with diagnostic and therapeutic endpoints) are needed. In this context, the large randomised ADIUVO-2 study is of major importance, although it will take several more years to be completed. We would thus like to emphasise once more that enrolment in clinical studies should always be offered to the patient if available (even if referral is necessary). From a pathophysiological point of view, targeting the Wnt and p53 pathway would be interesting. However, as these pathways are important for many cells in the body, developing drugs that target only tumour cells without unwanted systemic effects is challenging, but clinical trials are underway.

We see a combination of approaches to be further explored, applying not only to combining local and systemic therapies, but also for checkpoint inhibitors that are promising but frequently insufficient if used alone. We believe that there are two plausible approaches. First is the combination of checkpoint inhibitors and tyrosine kinase inhibitors. Second is that targeting glucocorticoid excess could be a prerequisite for successful immunotherapy in many patients with adrenocortical carcinoma. As glucocorticoid excess might be more apparent and more relevant at the tumour-cell level than systemically, anti-glucocorticoid therapy could also be an option in patients without obvious glucocorticoid excess. In addition, it might be necessary to use a block-and-replace strategy. Another promising treatment option might be CAR T cells, for which it would be crucial to address the intratumoural glucocorticoid excess. Exploiting theranostic concepts is a successful approach in other neuroendocrine tumours. Repurposed or specifically developed tracers have already been tested and achieved disease control in some patients.[136–138] Lastly, drugs targeting IGF-R1 have shown impressive success in individual patients, although they failed statistically in a randomised trial.[139] Again, combination therapy might be necessary to overcome intracellular compensatory mechanisms.

Although space constraints prevent us from providing an exhaustive list, we believe that additional research focused on the quality of life of patients with adrenocortical carcinoma is needed to take patients' preferences into account. International collaborations, such as ENSAT or the A5 network are thus needed and they have undoubtedly set the stage for major progress in the next ten years.

For the **ENSAT network** see https://ensat.org/

For the **A5 network** see https://adrenal-a5.org/

Contributors

MF and MT conceived the manuscript and wrote most of the draft. OK and SP drafted sections of the manuscript. MF and OK drafted the figures. All authors contributed to the literature search, extensively reviewed the manuscript, and approved the final version.

Declaration of interests

MF participated in a clinical trial on immunotherapy in adrenocortical carcinoma by Enterome (payment to the hospital). OK received a speaker's honorarium from HRA Rare Disease. SP received a speaker's honorarium from HRA Rare Disease and participated in an advisory board of Recordati Rare Diseases. MT received speakers' honoraria from HRA Rare Disease and Corcepts Therapeutics, and participated in advisory boards of HRA Rare Disease and Corcepts Therapeutics.

Acknowledgments

This Review was supported by funds from the Deutsche Forschungsgemeinschaft (CRC/Transregio 205/2 "The adrenal: central relay of health and disease" with a grant for MF) and the Associazione Italiana per la Ricerca sul Cancro (IG2019–23069 for MT). The funding agencies did not have any influence on the content of the manuscript or the decision to submit it for publication. None of the authors were paid to write this Review. All authors accept responsibility for submitting the manuscript for publication. We are deeply indebted to our patients and their families for their trust in us and their contribution to our research. We are grateful to Anna Southern and Adrian Wallwork for their thorough linguistic review.

References

1 Fassnacht M, Tsagarakis S, Terzolo M, et al. European Society of Endocrinology clinical practice guidelines on the management of adrenal incidentalomas, in collaboration with the European Network for the Study of Adrenal Tumors. *Eur J Endocrinol* 2023; **189:** G1–42.

2 Kerkhofs TM, Verhoeven RH, Van der Zwan JM, et al. Adrenocortical carcinoma: a population-based study on incidence and survival in the Netherlands since 1993. *Eur J Cancer* 2013; **49:** 2579–86.

3 Pedersen J, Jarløv AE, Rasmussen AK, Stochholm K. Incidence, treatment, and survival of adrenocortical carcinoma in Denmark 2003–19. *J Endocr Soc* 2024; **8:** bvae012.

4 Balderrama-Brondani V, Griffin AM, Owen TJ, et al. Incidence and geographical distribution of adrenocortical carcinoma: retrospective analysis of a state cancer registry. *Endocr Pract* 2024; **30:** 25–30.

5 Tella SH, Kommalapati A, Yaturu S, Kebebew E. Predictors of survival in adrenocortical carcinoma: an analysis from the National Cancer Database. *J Clin Endocrinol Metab* 2018; **103:** 3566–73.

6 Puglisi S, Calabrese A, Ferraù F, et al. New findings on presentation and outcome of patients with adrenocortical cancer: results from a national cohort study. *J Clin Endocrinol Metab* 2023; **108:** 2517–25.

7 Fassnacht M, Johanssen S, Quinkler M, et al. Limited prognostic value of the 2004 International Union Against Cancer staging classification for adrenocortical carcinoma: proposal for a Revised TNM classification. *Cancer* 2009; **115:** 243–50.

8 Daher M, Varghese J, Gruschkus SK, et al. Temporal trends in outcomes in patients with adrenocortical carcinoma: a multidisciplinary referral-center experience. *J Clin Endocrinol Metab* 2022; **107:** 1239–46.

9 Terzolo M, Fassnacht M. Endocrine tumours: our experience with the management of patients with non-metastatic adrenocortical carcinoma. *Eur J Endocrinol* 2022; **187:** R27–40.

10 Abiven G, Coste J, Groussin L, et al. Clinical and biological features in the prognosis of adrenocortical cancer: poor outcome of cortisol-secreting tumors in a series of 202 consecutive patients. *J Clin Endocrinol Metab* 2006; **91:** 2650–55.

11 Megerle F, Herrmann W, Schloetelburg W, et al. Mitotane monotherapy in patients with advanced adrenocortical carcinoma. *J Clin Endocrinol Metab* 2018; **103:** 1686–95.

12 Berruti A, Terzolo M, Sperone P, et al. Etoposide, doxorubicin and cisplatin plus mitotane in the treatment of advanced adrenocortical carcinoma: a large prospective phase II trial. *Endocr Relat Cancer* 2005; **12:** 657–66.

13 Icard P, Goudet P, Charpenay C, et al. Adrenocortical carcinomas: surgical trends and results of a 253-patient series from the French Association of Endocrine Surgeons study group. *World J Surg* 2001; **25:** 891–97.

14 Puglisi S, Perotti P, Cosentini D, et al. Decision-making for adrenocortical carcinoma: surgical, systemic, and endocrine management options. *Expert Rev Anticancer Ther* 2018; **18:** 1125–33.

15 Fassnacht M, Assie G, Baudin E, et al. Adrenocortical carcinomas and malignant phaeochromocytomas: ESMO-EURACAN clinical practice guidelines for diagnosis, treatment and follow-up. *Ann Oncol* 2020; **31:** 1476–90.

16 Fassnacht M, Dekkers OM, Else T, et al. European Society of Endocrinology clinical practice guidelines on the management of adrenocortical carcinoma in adults, in collaboration with the European Network for the Study of Adrenal Tumors. *Eur J Endocrinol* 2018; **179:** G1–46.

17 Yu K, Athimulam S, Saini J, et al. Serum steroid profiling in the diagnosis of adrenocortical carcinoma: a prospective cohort study. *J Clin Endocrinol Metab* 2024; published online Sept 4. https://doi.org/10.1210/clinem/dgae604.

18 Chortis V, Bancos I, Nijman T, et al. Urine steroid metabolomics as a novel tool for detection of recurrent adrenocortical carcinoma. *J Clin Endocrinol Metab* 2020; **105:** e307–18.

19 Kimpel O, Altieri B, Dischinger U, Fuss CT, Kurlbaum M, Fassnacht M. Early detection of recurrence and progress using serum steroid profiling by LC-MS/MS in patients with adrenocortical carcinoma. *Metabolites* 2023; **14:** 20.

20 Mantero F, Terzolo M, Arnaldi G, et al. A survey on adrenal incidentaloma in Italy. Study Group on Adrenal Tumors of the Italian Society of Endocrinology. *J Clin Endocrinol Metab* 2000; **85:** 637–44.

21 Gaujoux S, Mihai R, Carnaille B, et al, joint working group of ESES and ENSAT. European Society of Endocrine Surgeons (ESES) and European Network for the Study of Adrenal Tumours (ENSAT) recommendations for the surgical management of adrenocortical carcinoma. *Br J Surg* 2017; **104:** 358–76.

22 Uttinger KL, Reibetanz J, Diers J, et al. Volume-outcome relationship in adrenal surgery from 2009–17 in Germany—a retrospective study. *Eur J Endocrinol* 2023; **188:** lvac013.

23 Rajan S, Patel N, Stechman M, Balasubramanian SP, Mihai R, Aspinall S. Impact of adrenal surgeon volume on outcome: analysis of 4464 operations from the United Kingdom Registry of Endocrine and Thyroid Surgery (UKRETS). *Br J Surg* 2024; **111:** znae002.

24 Porpiglia F, Fiori C, Daffara FC, et al. Does nephrectomy during radical adrenalectomy for stage II adrenocortical cancer affect patient outcome? *J Endocrinol Invest* 2016; **39:** 465–71.

25 Autorino R, Bove P, De Sio M, et al. Open versus laparoscopic adrenalectomy for adrenocortical carcinoma: a meta-analysis of surgical and oncological outcomes. *Ann Surg Oncol* 2016; **23:** 1195–202.

26 Maurice MJ, Bream MJ, Kim SP, Abouassaly R. Surgical quality of minimally invasive adrenalectomy for adrenocortical carcinoma: a contemporary analysis using the National Cancer Database. *BJU Int* 2017; **119:** 436–43.

27 Dickson PV, Kim L, Yen TWF, et al. Evaluation, staging, and surgical management for adrenocortical carcinoma: an update from the SSO Endocrine and Head and Neck Disease Site Working Group. *Ann Surg Oncol* 2018; **25:** 3460–68.

28 Zheng GY, Li HZ, Deng JH, Zhang XB, Wu XC. Open adrenalectomy versus laparoscopic adrenalectomy for adrenocortical carcinoma: a retrospective comparative study on short-term oncologic prognosis. *OncoTargets Ther* 2018; **11:** 1625–32.

29 Gonzalez RJ, Shapiro S, Sarlis N, et al. Laparoscopic resection of adrenal cortical carcinoma: a cautionary note. *Surgery* 2005; **138:** 1078–85χ.

30 Langenhuijsen J, Birtle A, Klatte T, Porpiglia F, Timsit MO. Surgical management of adrenocortical carcinoma: impact of laparoscopic approach, lymphadenectomy, and surgical volume on outcomes-a systematic review and meta-analysis of the current literature. *Eur Urol Focus* 2016; **1:** 241–50.

31 Hu X, Yang WX, Shao YX, Dou WC, Xiong SC, Li X. Minimally invasive versus open adrenalectomy in patients with adrenocortical carcinoma: a meta-analysis. *Ann Surg Oncol* 2020; **27:** 3858–69.

32 Nakanishi H, Miangul S, Wang R, et al. Open versus laparoscopic surgery in the management of adrenocortical carcinoma: a systematic review and meta-analysis. *Ann Surg Oncol* 2023; **30:** 994–1005.

33 Gerry JM, Tran TB, Postlewait LM, et al. Lymphadenectomy for adrenocortical carcinoma: is there a therapeutic benefit? *Ann Surg Oncol* 2016; **23** (suppl 5)**:** 708–13.

34 Reibetanz J, Jurowich C, Erdogan I, et al. Impact of lymphadenectomy on the oncologic outcome of patients with adrenocortical carcinoma. *Ann Surg* 2012; **255:** 363–69.

35 Hendricks A, Müller S, Fassnacht M, et al. Impact of lymphadenectomy on the oncologic outcome of patients with adrenocortical carcinoma-a systematic review and meta-analysis. *Cancers* 2022; **14:** 291.

36 Reibetanz J, Rinn B, Kunz AS, et al. Patterns of lymph node recurrence in adrenocortical carcinoma: possible implications for primary surgical treatment. *Ann Surg Oncol* 2019; **26:** 531–38.

37 Sada A, Glasgow AE, Lyden ML, et al. Informing therapeutic lymphadenectomy: location of regional metastatic lymph nodes in adrenocortical carcinoma. *Am J Surg* 2022; **223:** 1042–45.

38 Assad A, Barletta F, Incesu RB, et al. Prognostic significance of lymph node count in surgically treated patients with T_{2-4} stage nonmetastatic adrenocortical carcinoma. *Urol Oncol* 2024; **42:** 248.e1–9.

39 Bednarski BK, Habra MA, Phan A, et al. Borderline resectable adrenal cortical carcinoma: a potential role for preoperative chemotherapy. *World J Surg* 2014; **38:** 1318–27.

40 Berruti A, Amoroso V, Gallo F, et al. Pathologic complete response as a potential surrogate for the clinical outcome in patients with breast cancer after neoadjuvant therapy: a meta-regression of 29 randomized prospective studies. *J Clin Oncol* 2014; **32:** 3883–91.

41 Livhits M, Li N, Yeh MW, Harari A. Surgery is associated with improved survival for adrenocortical cancer, even in metastatic disease. *Surgery* 2014; **156:** 1531–41.

42 Wang S, Gao WC, Chen SS, et al. Primary site surgery for metastatic adrenocortical carcinoma improves survival outcomes: an analysis of a population-based database. *OncoTargets Ther* 2017; **10:** 5311–15.

43 Johanssen S, Hahner S, Saeger W, et al. Deficits in the management of patients with adrenocortical carcinoma in Germany. *Dtsch Arztebl Int* 2010; **107:** 885–91.

44 Duregon E, Volante M, Bollito E, et al. Pitfalls in the diagnosis of adrenocortical tumors: a lesson from 300 consultation cases. *Hum Pathol* 2015; **46:** 1799–807.

45 Sbiera S, Schmull S, Assie G, et al. High diagnostic and prognostic value of steroidogenic factor-1 expression in adrenal tumors. *J Clin Endocrinol Metab* 2010; **95:** E161–71.

46 Weiss LM. Comparative histologic study of 43 metastasizing and nonmetastasizing adrenocortical tumors. *Am J Surg Pathol* 1984; **8:** 163–69.

47 Weiss LM, Medeiros LJ, Vickery AL Jr. Pathologic features of prognostic significance in adrenocortical carcinoma. *Am J Surg Pathol* 1989; **13:** 202–06.

48 Papotti M, Libè R, Duregon E, Volante M, Bertherat J, Tissier F. The Weiss score and beyond--histopathology for adrenocortical carcinoma. *Horm Cancer* 2011; **2:** 333–40.

49 van Slooten H, Schaberg A, Smeenk D, Moolenaar AJ. Morphologic characteristics of benign and malignant adrenocortical tumors. *Cancer* 1985; **55:** 766–73.

50 Aubert S, Wacrenier A, Leroy X, et al. Weiss system revisited: a clinicopathologic and immunohistochemical study of 49 adrenocortical tumors. *Am J Surg Pathol* 2002; **26:** 1612–19.

51 Duregon E, Cappellesso R, Maffeis V, et al. Validation of the prognostic role of the "Helsinki Score" in 225 cases of adrenocortical carcinoma. *Hum Pathol* 2017; **62:** 1–7.

52 Pennanen M, Heiskanen I, Sane T, et al. Helsinki score-a novel model for prediction of metastases in adrenocortical carcinomas. *Hum Pathol* 2015; **46:** 404–10.

53 Duregon E, Fassina A, Volante M, et al. The reticulin algorithm for adrenocortical tumor diagnosis: a multicentric validation study on 245 unpublished cases. *Am J Surg Pathol* 2013; **37:** 1433–40.

54 Bisceglia M, Ludovico O, Di Mattia A, et al. Adrenocortical oncocytic tumors: report of 10 cases and review of the literature. *Int J Surg Pathol* 2004; **12:** 231–43.

55 Wong DD, Spagnolo DV, Bisceglia M, Havlat M, McCallum D, Platten MA. Oncocytic adrenocortical neoplasms—a clinicopathologic study of 13 new cases emphasizing the importance of their recognition. *Hum Pathol* 2011; **42:** 489–99.

56 Beuschlein F, Weigel J, Saeger W, et al. Major prognostic role of Ki67 in localized adrenocortical carcinoma after complete resection. *J Clin Endocrinol Metab* 2015; **100:** 841–49.

57 Lu H, Papathomas TG, van Zessen D, et al. Automated Selection of Hotspots (ASH): enhanced automated segmentation and adaptive step finding for Ki67 hotspot detection in adrenal cortical cancer. *Diagn Pathol* 2014; **9:** 216.

58 Papathomas TG, Pucci E, Giordano TJ, et al. An international Ki67 reproducibility study in adrenal cortical carcinoma. *Am J Surg Pathol* 2016; **40:** 569–76.

59 Lughezzani G, Sun M, Perrotte P, et al. The European Network for the Study of Adrenal Tumors staging system is prognostically superior to the International Union Against Cancer-staging system: a North American validation. *Eur J Cancer* 2010; **46:** 713–19.

60 Libé R, Borget I, Ronchi CL, et al. Prognostic factors in stage III–IV adrenocortical carcinomas (ACC): an European Network for the Study of Adrenal Tumor (ENSAT) study. *Ann Oncol* 2015; **26:** 2119–25.

61 Elhassan YS, Altieri B, Berhane S, et al. S-GRAS score for prognostic classification of adrenocortical carcinoma: an international, multicenter ENSAT study. *Eur J Endocrinol* 2021; **186:** 25–36.

62 Terzolo M, Fassnacht M, Perotti P, et al. Adjuvant mitotane versus surveillance in low-grade, localised adrenocortical carcinoma (ADIUVO): an international, multicentre, open-label, randomised, phase 3 trial and observational study. *Lancet Diabetes Endocrinol* 2023; **11:** 720–30.

63 Berruti A, Fassnacht M, Haak H, et al. Prognostic role of overt hypercortisolism in completely operated patients with adrenocortical cancer. *Eur Urol* 2014; **65:** 832–38.

64 Margonis GA, Kim Y, Tran TB, et al. Outcomes after resection of cortisol-secreting adrenocortical carcinoma. *Am J Surg* 2016; **211:** 1106–13.

65 Sada A, Foster TR, Al-Ward R, et al. The effect of hormonal secretion on survival in adrenocortical carcinoma: a multi-center study. *Surgery* 2024; **175:** 80–89.

66 de Reyniès A, Assié G, Rickman DS, et al. Gene expression profiling reveals a new classification of adrenocortical tumors and identifies molecular predictors of malignancy and survival. *J Clin Oncol* 2009; **27:** 1108–15.

67 Lippert J, Altieri B, Morrison B, et al. Prognostic role of targeted methylation analysis in paraffin-embedded samples of adrenocortical carcinoma. *J Clin Endocrinol Metab* 2022; **107:** 2892–99.

68 Mohan DR, Lerario AM, Else T, et al. Targeted assessment of G0S2 methylation identifies a rapidly recurrent, routinely fatal molecular subtype of adrenocortical carcinoma. *Clin Cancer Res* 2019; **25:** 3276–88.

69 Assié G, Jouinot A, Fassnacht M, et al. Value of molecular classification for prognostic assessment of adrenocortical carcinoma. *JAMA Oncol* 2019; **5:** 1440–47.

70 Petr EJ, Else T. Adrenocortical carcinoma (ACC): when and why should we consider germline testing? *Presse Med* 2018; **47:** e119–25.

71 Scatolini M, Grisanti S, Tomaiuolo P, et al. Germline NGS targeted analysis in adult patients with sporadic adrenocortical carcinoma. *Eur J Cancer* 2024; **205:** 114088.

72 Puglisi S, Calabrese A, Basile V, et al. New perspectives for mitotane treatment of adrenocortical carcinoma. *Best Pract Res Clin Endocrinol Metab* 2020; **34:** 101415.

73 Terzolo M, Angeli A, Fassnacht M, et al. Adjuvant mitotane treatment for adrenocortical carcinoma. *N Engl J Med* 2007; **356:** 2372–80.

74 Baudin E, Pellegriti G, Bonnay M, et al. Impact of monitoring plasma 1,1-dichlorodiphenildichloroethane (o,p'DDD) levels on the treatment of patients with adrenocortical carcinoma. *Cancer* 2001; **92:** 1385–92.

75 Fassnacht M, Terzolo M, Allolio B, et al. Combination chemotherapy in advanced adrenocortical carcinoma. *N Engl J Med* 2012; **366:** 2189–97.

76 Sperone P, Ferrero A, Daffara F, et al. Gemcitabine plus metronomic 5-fluorouracil or capecitabine as a second-/third-line chemotherapy in advanced adrenocortical carcinoma: a multicenter phase II study. *Endocr Relat Cancer* 2010; **17:** 445–53.

77 Henning JEK, Deutschbein T, Altieri B, et al. Gemcitabine-based chemotherapy in adrenocortical carcinoma: a multicenter study of efficacy and predictive factors. *J Clin Endocrinol Metab* 2017; **102:** 4323–32.

78 Raj N, Zheng Y, Kelly V, et al. PD-1 blockade in advanced adrenocortical carcinoma. *J Clin Oncol* 2020; **38:** 71–80.

79 Habra MA, Stephen B, Campbell M, et al. Phase II clinical trial of pembrolizumab efficacy and safety in advanced adrenocortical carcinoma. *J Immunother Cancer* 2019; **7:** 253.

80 Kroiss M, Megerle F, Kurlbaum M, et al. Objective response and prolonged disease control of advanced adrenocortical carcinoma with cabozantinib. *J Clin Endocrinol Metab* 2020; **105:** 1461–68.

81 Campbell MT, Balderrama-Brondani V, Jimenez C, et al. Cabozantinib monotherapy for advanced adrenocortical carcinoma: a single-arm, phase 2 trial. *Lancet Oncol* 2024; **25:** 649–57.

82 Cosentini D, Badalamenti G, Grisanti S, et al. Activity and safety of temozolomide in advanced adrenocortical carcinoma patients. *Eur J Endocrinol* 2019; **181:** 681–89.

83 Tang Y, Liu Z, Zou Z, Liang J, Lu Y, Zhu Y. Benefits of adjuvant mitotane after resection of adrenocortical carcinoma: a systematic review and meta-analysis. *BioMed Res Int* 2018; **2018:** 9362108.

84 Calabrese A, Basile V, Puglisi S, et al. Adjuvant mitotane therapy is beneficial in non-metastatic adrenocortical carcinoma at high risk of recurrence. *Eur J Endocrinol* 2019; **180:** 387–96.

85 Basile V, Puglisi S, Altieri B, et al. What is the optimal duration of adjuvant mitotane therapy in adrenocortical carcinoma? An unanswered question. *J Pers Med* 2021; **11:** 269.

86 Hovi L, Wikström S, Vettenranta K, Heikkilä P, Saarinen-Pihkala UM. Adrenocortical carcinoma in children: a role for etoposide and cisplatin adjuvant therapy? Preliminary report. *Med Pediatr Oncol* 2003; **40:** 324–26.

87 Khan TS, Imam H, Juhlin C, et al. Streptozocin and o,p'DDD in the treatment of adrenocortical cancer patients: long-term survival in its adjuvant use. *Ann Oncol* 2000; **11:** 1281–87.

88 Kimpel O, Bedrose S, Megerle F, et al. Adjuvant platinum-based chemotherapy in radically resected adrenocortical carcinoma: a cohort study. *Br J Cancer* 2021; **125:** 1233–38.

89 Rodriguez-Galindo C, Krailo MD, Pinto EM, et al. Treatment of pediatric adrenocortical carcinoma with surgery, retroperitoneal lymph node dissection, and chemotherapy: The Children's Oncology Group ARAR0332 protocol. *J Clin Oncol* 2021; **39:** 2463–73.

90 Gharzai LA, Green MD, Griffith KA, et al. Adjuvant radiation improves recurrence-free survival and overall survival in adrenocortical carcinoma. *J Clin Endocrinol Metab* 2019; **104:** 3743–50.

91 Wu K, Liu X, Liu Z, Lu Y, Wang X, Li X. Benefit of postoperative radiotherapy for patients with nonmetastatic adrenocortical carcinoma: a population-based analysis. *J Natl Compr Canc Netw* 2021; **19:** 1425–32.

92 Zhu J, Zheng Z, Shen J, et al. Efficacy of adjuvant radiotherapy for treatment of adrenocortical carcinoma: a retrospective study and an updated meta-analysis. *Radiat Oncol* 2020; **15:** 118.

93 Wu L, Chen J, Su T, et al. Efficacy and safety of adjuvant radiation therapy in localized adrenocortical carcinoma. *Front Endocrinol* 2024; **14:** 1308231.

94 Fassnacht M, Hahner S, Polat B, et al. Efficacy of adjuvant radiotherapy of the tumor bed on local recurrence of adrenocortical carcinoma. *J Clin Endocrinol Metab* 2006; **91:** 4501–04.

95 Habra MA, Ejaz S, Feng L, et al. A retrospective cohort analysis of the efficacy of adjuvant radiotherapy after primary surgical resection in patients with adrenocortical carcinoma. *J Clin Endocrinol Metab* 2013; **98:** 192–97.

96 Srougi V, de Bessa J Jr, Tanno FY, et al. Adjuvant radiotherapy for the primary treatment of adrenocortical carcinoma: are we offering the best? *Int Braz J Urol* 2017; **43:** 841–48.

97 Sinclair TJ, Gillis A, Alobuia WM, Wild H, Kebebew E. Surgery for adrenocortical carcinoma: when and how? *Best Pract Res Clin Endocrinol Metab* 2020; **34:** 101408.

98 Grubbs EG, Callender GG, Xing Y, et al. Recurrence of adrenal cortical carcinoma following resection: surgery alone can achieve results equal to surgery plus mitotane. *Ann Surg Oncol* 2010; **17:** 263–70.

99 Erdogan I, Deutschbein T, Jurowich C, et al. The role of surgery in the management of recurrent adrenocortical carcinoma. *J Clin Endocrinol Metab* 2013; **98:** 181–91.

100 Calabrese A, Puglisi S, Borin C, et al. The management of postoperative disease recurrence in patients with adrenocortical carcinoma: a retrospective study in 106 patients. *Eur J Endocrinol* 2023; **188:** lvad002.

101 Kimpel O, Dischinger U, Altieri B, et al. Current evidence on local therapies in advanced adrenocortical carcinoma. *Horm Metab Res* 2024; **56:** 91–98.

102 Kimpel O, Schindler P, Schmidt-Pennington L, et al. Efficacy and safety of radiation therapy in advanced adrenocortical carcinoma. *Br J Cancer* 2023; **128:** 586–93.

103 Roux C, Boileve A, Faron M, et al. Loco-regional therapies in oligometastatic adrenocortical carcinoma. *Cancers* 2022; **14:** 2730.

104 Hescot S, Debien V, Hadoux J, et al. Outcome of adrenocortical carcinoma patients included in early phase clinical trials: results from the French network ENDOCAN-COMETE. *Eur J Cancer* 2023; **189:** 112917.

105 Carneiro BA, Konda B, Costa RB, et al. Nivolumab in metastatic adrenocortical carcinoma: results of a phase 2 trial. *J Clin Endocrinol Metab* 2019; **104:** 6193–200.

106 Le Tourneau C, Hoimes C, Zarwan C, et al. Avelumab in patients with previously treated metastatic adrenocortical carcinoma: phase 1b results from the JAVELIN solid tumor trial. *J Immunother Cancer* 2018; **6:** 111.

107 Remde H, Schmidt-Pennington L, Reuter M, et al. Outcome of immunotherapy in adrenocortical carcinoma: a retrospective cohort study. *Eur J Endocrinol* 2023; **188:** 485–93.

108 Bedrose S, Miller KC, Altameemi L, et al. Combined lenvatinib and pembrolizumab as salvage therapy in advanced adrenal cortical carcinoma. *J Immunother Cancer* 2020; **8:** e001009.

109 Patel SP, Othus M, Chae YK, et al. Phase II basket trial of Dual Anti-CTLA-4 and Anti-PD-1 blockade in Rare Tumors (DART) SWOG S1609: adrenocortical carcinoma cohort. *J Immunother Cancer* 2024; **12:** e009074.

110 Kroiss M, Quinkler M, Lutz WK, Allolio B, Fassnacht M. Drug interactions with mitotane by induction of CYP3A4 metabolism in the clinical management of adrenocortical carcinoma. *Clin Endocrinol* 2011; **75:** 585–91.

111 Altieri B, Ronchi CL, Kroiss M, Fassnacht M. Next-generation therapies for adrenocortical carcinoma. *Best Pract Res Clin Endocrinol Metab* 2020; **34:** 101434.

112 Assié G, Letouzé E, Fassnacht M, et al. Integrated genomic characterization of adrenocortical carcinoma. *Nat Genet* 2014; **46:** 607–12.

113 Zheng S, Cherniack AD, Dewal N, et al. Comprehensive pan-genomic characterization of adrenocortical carcinoma. *Cancer Cell* 2016; **29:** 723–36.

114 Tourigny DS, Altieri B, Secener KA, et al. Cellular landscape of adrenocortical carcinoma at single-nuclei resolution. *Mol Cell Endocrinol* 2024; **590:** 112272.

115 Lerario AM, Mohan DR, Hammer GD. Update on biology and genomics of adrenocortical carcinomas: rationale for emerging therapies. *Endocr Rev* 2022; **43:** 1051–73.

116 Lippert J, Fassnacht M, Ronchi CL. The role of molecular profiling in adrenocortical carcinoma. *Clin Endocrinol* 2022; **97:** 460–72.

117 Ghosh C, Hu J, Kebebew E. Advances in translational research of the rare cancer type adrenocortical carcinoma. *Nat Rev Cancer* 2023; **23:** 805–24.

118 Pozdeyev N, Fishbein L, Gay LM, et al. Targeted genomic analysis of 364 adrenocortical carcinomas. *Endocr Relat Cancer* 2021; **28:** 671–81.

119 Poirier J, Godemel S, Mourot A, et al. Central hypothyroidism is frequent during mitotane therapy in adrenocortical cancer patients: prevalence and timeline. *J Clin Endocrinol Metab* 2023; **108:** 2336–42.

120 Basile V, Puglisi S, Calabrese A, et al. Unwanted hormonal and metabolic effects of postoperative adjuvant mitotane treatment for adrenocortical cancer. *Cancers* 2020; **12:** 2615.

121 Vikner ME, Krogh J, Daugaard G, Andreassen M. Metabolic and hormonal side effects of mitotane treatment for adrenocortical carcinoma: a retrospective study in 50 Danish patients. *Clin Endocrinol* 2021; **94:** 141–49.

122 Ehrlich MI, Labadie BW, Bates SE, Fojo T. Mitotane and the myth of 14 mg/L. *Lancet Oncol* 2024; **25:** 12–15.

123 Reidy-Lagunes DL, Lung B, Untch BR, et al. Complete responses to mitotane in metastatic adrenocortical carcinoma-a new look at an old drug. *Oncologist* 2017; **22:** 1102–06.

124 Turla A, Laganà M, Grisanti S, et al. Supportive therapies in patients with advanced adrenocortical carcinoma submitted to standard EDP-M regimen. *Endocrine* 2022; **77:** 438–43.

125 Herrstedt J, Clark-Snow R, Ruhlmann CH, et al. 2023 MASCC and ESMO guideline update for the prevention of chemotherapy- and radiotherapy-induced nausea and vomiting. *ESMO Open* 2024; **9:** 102195.

126 Corcuff JB, Young J, Masquefa-Giraud P, Chanson P, Baudin E, Tabarin A. Rapid control of severe neoplastic hypercortisolism with metyrapone and ketoconazole. *Eur J Endocrinol* 2015; **172:** 473–81.

127 Claps M, Cerri S, Grisanti S, et al. Adding metyrapone to chemotherapy plus mitotane for Cushing's syndrome due to advanced adrenocortical carcinoma. *Endocrine* 2018; **61:** 169–72.

128 Tabarin A, Haissaguerre M, Lassole H, et al. Efficacy and tolerance of osilodrostat in patients with Cushing's syndrome due to adrenocortical carcinomas. *Eur J Endocrinol* 2022; **186:** K1–4.

129 Berruti A, Libè R, Laganà M, et al. Morbidity and mortality of bone metastases in advanced adrenocortical carcinoma: a multicenter retrospective study. *Eur J Endocrinol* 2019; **180:** 311–20.

130 Fallon M, Giusti R, Aielli F, et al. Management of cancer pain in adult patients: ESMO Clinical Practice Guidelines. *Ann Oncol* 2018; **29** (suppl 4)**:** iv166–91.

131 Steenaard RV, Kerkhofs TMA, Zijlstra M, et al. Health-related quality of life in adrenocortical carcinoma: development of the disease-specific questionnaire ACC-QOL and results from the PROFILES registry. *Cancers* 2022; **14:** 1366.

132 Stiefel F, Bourquin C, Salmon P, et al. Communication and support of patients and caregivers in chronic cancer care: ESMO clinical practice guideline. *ESMO Open* 2024; **9:** 103496.

133 Ferrell BR, Temel JS, Temin S, et al. Integration of palliative care into standard oncology care: American Society of Clinical Oncology clinical practice guideline update. *J Clin Oncol* 2017; **35:** 96–112.

134 Sanders JJ, Temin S, Ghoshal A, et al. Palliative care for patients with cancer: ASCO guideline update. *J Clin Oncol* 2024; **42:** 2336–57.

135 Ruggiero E, Tizianel I, Caccese M, et al. Advanced adrenocortical carcinoma: from symptoms control to palliative care. *Cancers* 2022; **14:** 5901.

136 Grisanti S, Filice A, Basile V, et al. Treatment with 90Y/177Lu-DOTATOC in patients with metastatic adrenocortical carcinoma expressing somatostatin receptors. *J Clin Endocrinol Metab* 2020; **105:** dgz091.

137 Hahner S, Kreissl MC, Fassnacht M, et al. [131I]iodometomidate for targeted radionuclide therapy of advanced adrenocortical carcinoma. *J Clin Endocrinol Metab* 2012; **97:** 914–22.

138 Hahner S, Hartrampf PE, Mihatsch PW, et al. Targeting 11-Beta Hydroxylase With [131I]IMAZA: a novel approach for the treatment of advanced adrenocortical carcinoma. *J Clin Endocrinol Metab* 2022; **107:** e1348–55.

139 Fassnacht M, Berruti A, Baudin E, et al. Linsitinib (OSI-906) versus placebo for patients with locally advanced or metastatic adrenocortical carcinoma: a double-blind, randomised, phase 3 study. *Lancet Oncol* 2015; **16:** 426–35.

Copyright © 2025 The Author(s). Published by Elsevier Ltd. This is an Open Access article under the CC BY 4.0 license